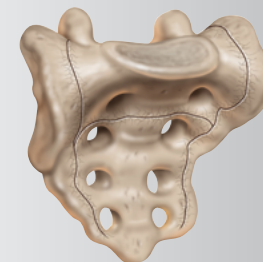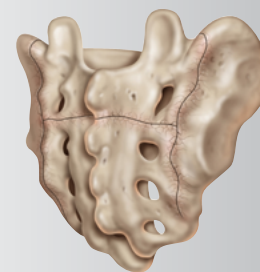


SACROPLASTY TECHNIQUE GUIDE



Start



Medtronic

Further, Together



BACKGROUND

EXPANDED PROCEDURAL SOLUTIONS

PATIENT POSITIONING AND IMAGING

ACCESSING THE SACRUM

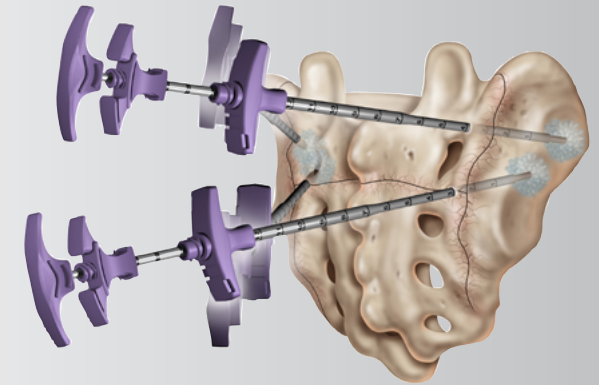
Long-Axis Technique

- Imaging
- Accessing the Sacrum
- Cement Injection

Short-Axis Technique

- Imaging
- Accessing the Sacrum
- Cement Injection

IMPORTANT PRODUCT INFORMATION



BACKGROUND

Sacroplasty can be used to treat painful sacral insufficiency fractures.^{1,2}

This procedure involves:

- Percutaneously inserting one or more bone needles into the sacrum
- Fluoroscopy and/or CT visual guidance
- Bone cement injected under imaging to treat the lesion and stabilize the fracture

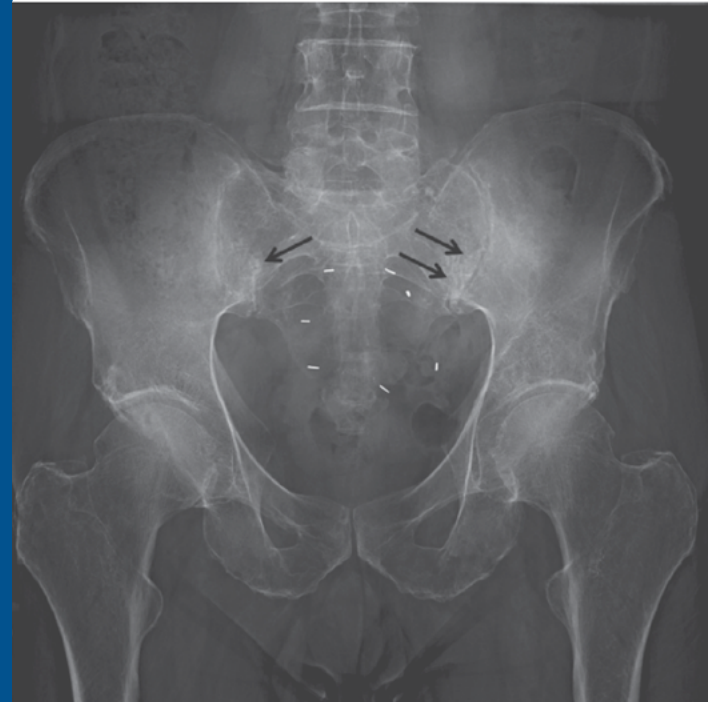
SIFs can be confirmed with radiographic imaging as shown here.³

1. Ortiz AO and Brook AL. *Tech Vasc Interv Radiol.* 2009;12(1):51-63.
2. Kortman K, et al. *J Neurointerv Surg.* 2013;5(5):461-466.
3. Beall D. In: DePalma MJ, editor. *iSpine: Evidence-Based Interventional Spine Care.* New York, NJ: *Demos Medical Publishing,* 2011: 482-496.

DIAGNOSING SIFS

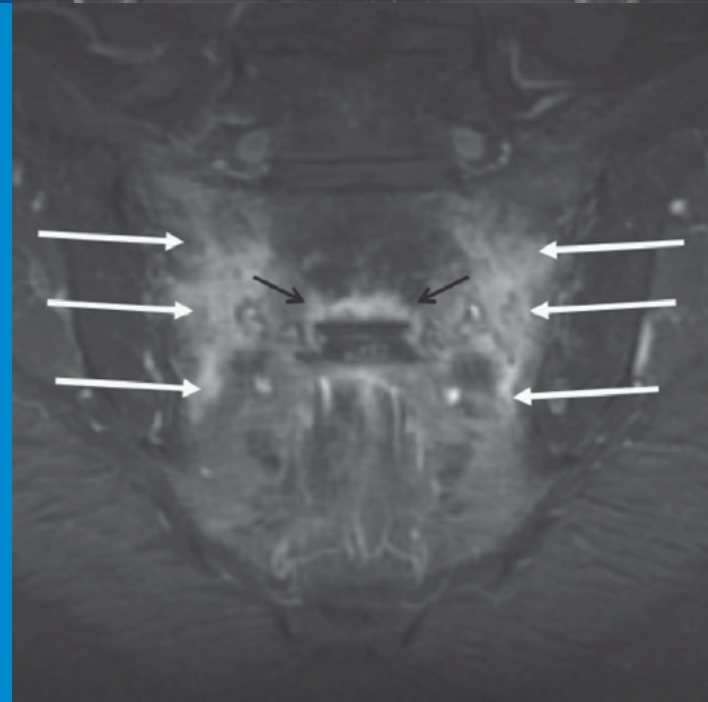
Conventional AP radiograph of the pelvis indicates:

- Sclerotic regions along the midportion of the sacrum, parallel to the inferior portion of the sacroiliac joint (black arrows)
- Bilateral SIFs



Coronal fast spin echo T2-weighted MRI indicates:

- Regions of increased signal in the lateral portions of the sacrum (white arrows) consistent with SIFs
- A horizontal component of the SIFs located centrally within the sacrum (between the black arrows)



EXPANDED PROCEDURAL SOLUTIONS DESIGNED TO FIT YOUR NEEDS

Kyphon™ Access Tools can be used for percutaneous access to bone and the delivery of bone cement during sacroplasty, kyphoplasty, and vertebroplasty procedures.

ACCESS OPTIONS

Access		8 Ga	10 Ga	11 Ga	13 Ga
Osteo Introducer	<i>Trocar</i>	X	X	X	X
	<i>Diamond</i>	X	X		
	<i>Bevel</i>	X	X	X	X
	<i>Matched Bevel</i>			X	X
	<i>Drill-Tip</i>		X		
Cannulated	<i>Blunt</i>	X			
	<i>Drill-Tip</i>	X			
Cement Delivery					
Cement Injection	<i>Bone Fillers</i>	X	X		
	<i>Cement Delivery System</i>	X	X	X	X
	<i>Curved Bone Filler</i>		X		
Bone Biopsy Option					
	<i>Biopsy</i>	X	X	X	X



EXPANDED PROCEDURAL SOLUTIONS EXTENSIVE BONE CEMENT EXPERIENCE

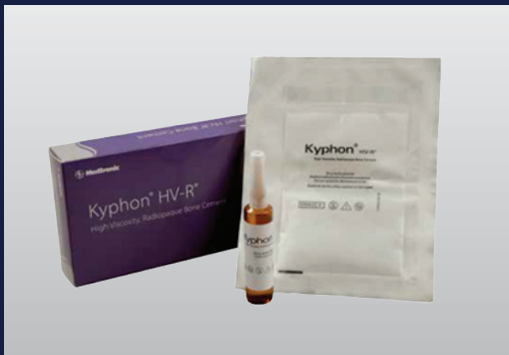Kyphon Xpede™ Bone Cement

- “Quick-to-dough” cement provides ease of handling
- Allows sufficient time for careful, minimally invasive introduction



Kyphon HV-R™ Bone Cement

- Long history of clinical use



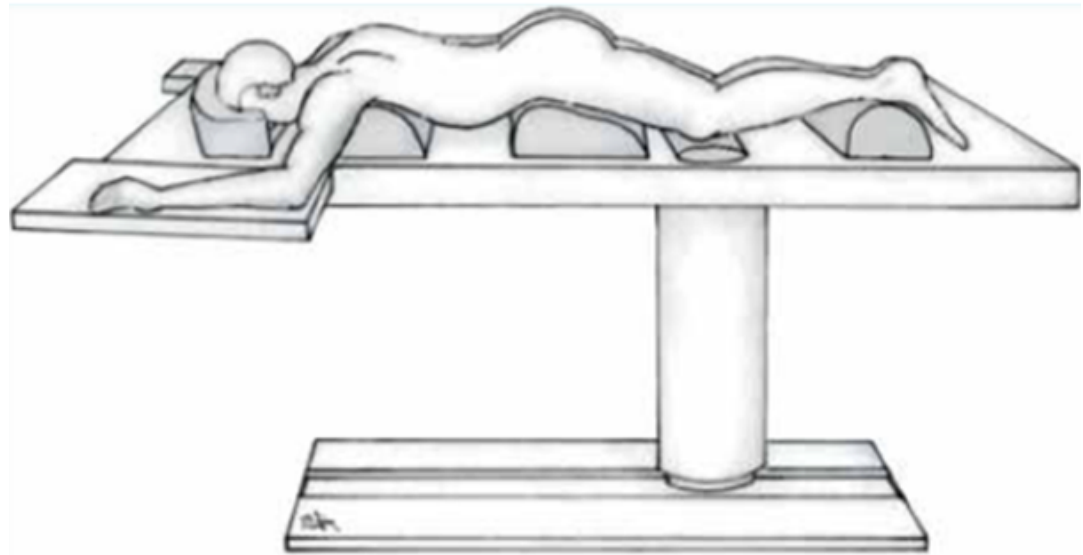
Description	CFN	Includes
8 Gauge A La Carte		
Trocar & Diamond	T15J	Trocar Stylet, Diamond Stylet, Precision Drill, Access Cannulas (2)
Bevel	T15K	Bevel Stylet, Access Cannulas (1)
Drill-Tip	A20A*	Drill-Tip Stylet, Access Cannulas (2)
	T15E*	Drill-Tip Stylet, Access Cannulas (2), Precision Drill, Blunt Guidewires (2), Sharp Guidewires (2)
Blunt	T15D*	Blunt Stylet, Access Cannulas (2), Precision Drill, Blunt Guidewires (2), Sharp Guidewires (2)
<i>*May require 11 Gauge Bone Access Needle — Diamond (A02A), Trocar (A02B), Bevel (A02C)</i>		
Bone Fillers	F04B	Kyphon™ Bone Filler Device
	F04C	Kyphon™ Directional Bone Filler Device
Cement Delivery System	CDS3A + CC02A	Kyphon™ Cement Delivery Gun, Bone Filler Devices (2)
Biopsy	F05A	Kyphon™ Bone Biopsy Device
10 Gauge A La Carte		
Diamond & Bevel	T34A	Diamond Stylet, Bevel Stylet, Access Cannulas (2), Precision Drill, Tamp
Trocar	T34B	Trocar Stylet, Access Cannulas (1)
Drill-Tip	T34C	Drill-Tip Stylet, Access Cannulas (1)
Diamond	T34D	Diamond Stylet, Access Cannulas (1)
Bevel	T34E	Bevel Stylet, Access Cannulas (1)
Bone Fillers	F06A	Kyphon Express™ Bone Filler Device
	F06B	Kyphon Express™ Directional Bone Filler Device
Cement Delivery System	CDS2A + CC02A	Kyphon™ Cement Delivery Gun, Bone Filler Devices (2), Cement Cartridges (2)
10 Gauge Kit		
Trocar Kit	VPK1002	Trocar Stylet, Access Cannulas (1), Cement Delivery Gun, CDS Cartridges (2)
Additional Trocar Access	VPT01B	Trocar Stylet, Access Cannulas (1)
Optional Curved Bone Filler	VPT02A	Kyphon Kurve™ Curved Bone Filler Device
11 Gauge Kits		
Trocar & Bevel Kit	VPK011D	Trocar Stylet, Bevel Stylet, Access Cannulas (1), Cement Delivery Gun, CDS Cartridges (2)
Additional Trocar & Bevel Access	VPT11D	Trocar Stylet, Bevel Stylet, Access Cannulas (1)
Matched Bevel Kit	VPK011B	Matched Bevel Stylet, Access Cannulas (1), Cement Delivery Gun, CDS Cartridges (2)
Additional Matched Bevel Access	VPT11B	Matched Bevel Stylet, Access Cannulas (1)
13 Ga Biopsy	VPB11	Bone Biopsy Device 13 Ga
13 Gauge Kits		
Trocar & Bevel Kit	VPK013D	Trocar Stylet, Bevel Stylet, Access Cannulas (1), Cement Delivery Gun, CDS Cartridges (2)
Additional Trocar & Bevel Access	VPT13D	Trocar Stylet, Bevel Stylet, Access Cannulas (1)
Matched Bevel Kit	VPK013B	Matched Bevel Stylet, Access Cannulas (1), Cement Delivery Gun, CDS Cartridges (2)
Additional Matched Bevel Access	VPT13B	Matched Bevel Stylet, Access Cannulas (1)
15 Ga Biopsy Device	VPB13	Bone Biopsy Device 15 Ga



PATIENT POSITIONING AND IMAGING

Patient placement

- Place patient in prone position on radiolucent table — this allows for AP and lateral imaging.
- Place rolls under chest and hips.
- Pad face, lower legs, and elbows.



PATIENT POSITIONING AND IMAGING

Image guidance

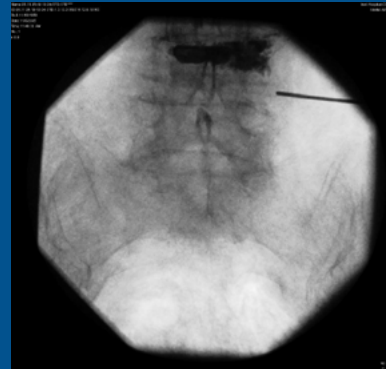
Sacroplasty can be performed using CT or fluoroscopy to:

- Guide needle placement
- Monitor polymethylmethacrylate (PMMA) cement delivery

IMAGING VIEWS OF THE SACRUM AND KEY ANATOMICAL LANDMARKS

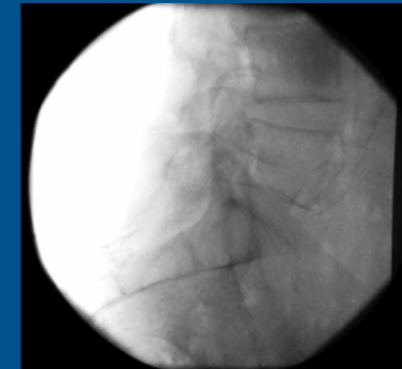
AP View

- Sacral alae
- S1 pedicles
- S1 foramina
- Sacral crest
- Sacroiliac joint



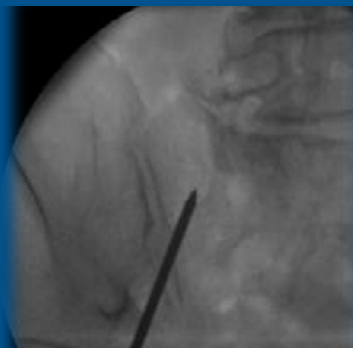Lateral View

- S1 superior endplate
- Anterior sacral body wall
- Alar slope
- S1-S2 disc space
- Sacral crests



SI View

- Sacral alae
- S1 pedicles
- S1 foramina
- Sacral crest
- Sacroiliac joint



- In anatomical position, the S1 superior endplate is tilted inferiorly.
- Image intensifier must be tilted cephalad to get a true AP image of the S1 endplates.



ACCESSING THE SACRUM

Pre-op planning

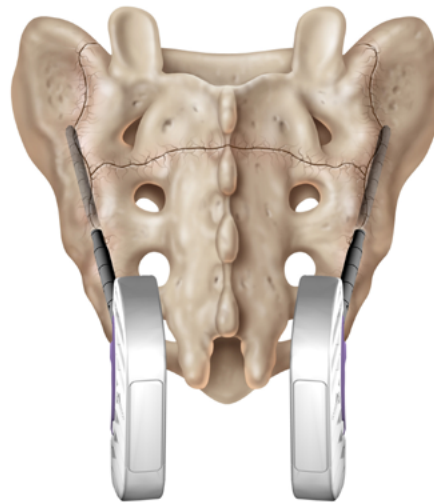
There are two primary techniques for accessing and subsequently treating SIFs:

- Long axis
- Short axis

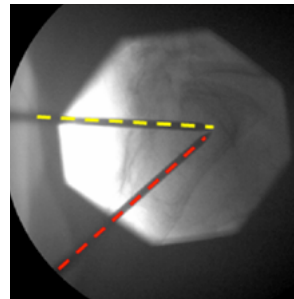
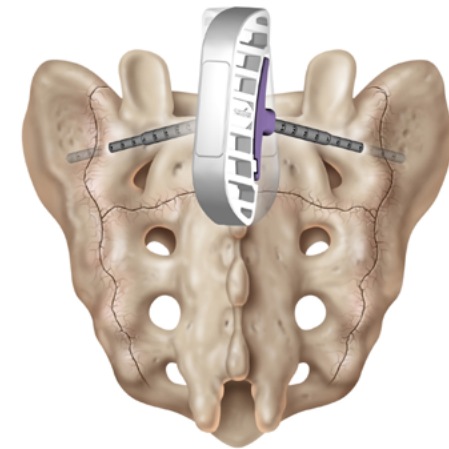
A detailed pre-operative evaluation should be performed to:

- Identify the location of the fracture(s)
- Determine the safest procedural approach per the patient's anatomical and clinical conditions

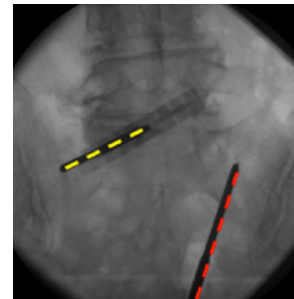
Bi-Lateral Long Axis



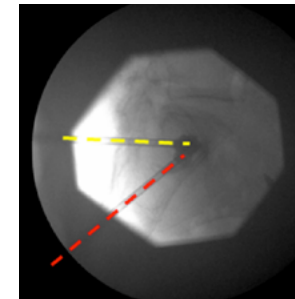
Bi-Lateral Short Axis



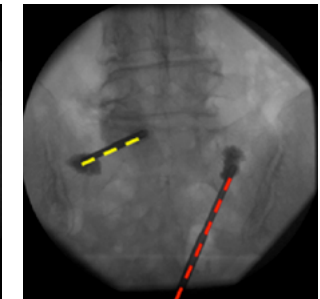
Lateral view



AP view



Lateral view with cement



AP view with cement

- Long-Axis Technique
- Short-Axis Technique

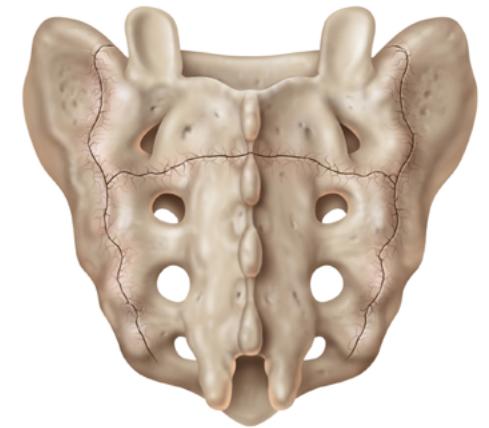


ACCESSING THE SACRUM

Long-axis technique

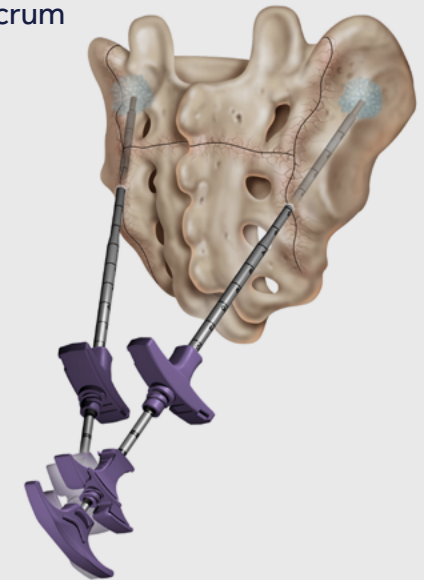
Imaging

- In the frontal plane, rotate the image intensifier cephalad to an AP plane.
- Ensure that a direct AP view is obtained by rotating the image intensifier to place the spinous processes in the center of the vertebral body.
- Rotate the image intensifier to the side opposite the treatment location to approximately 20° to 30° or to an angle along the longitudinal axis of the SI joint that aligns the inferior portion of the joint.
- Choose a starting point halfway between the SI joint and a vertical line that joins the medial borders of the sacral neural foramina.



Posterior view
of the sacrum

Oblique view of
the sacrum

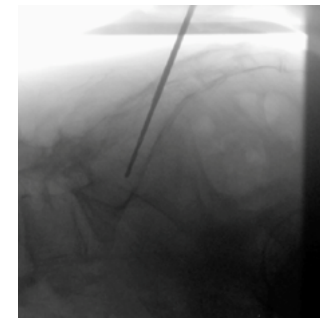
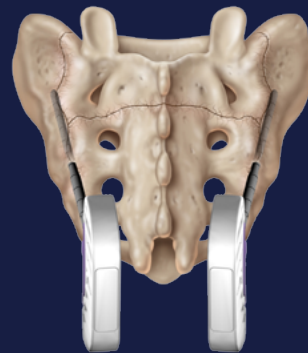


ACCESSING THE SACRUM

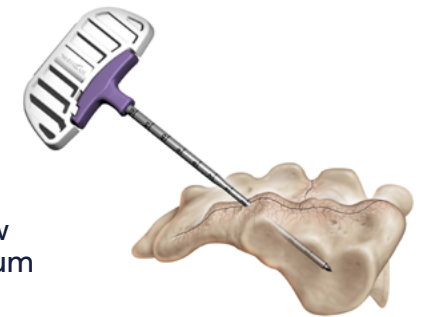Long-axis technique

1. Anesthetize the skin in the location of the starting point, and make a stab incision with a scalpel blade.
2. Insert the Osteo Introducer Device parallel to the image intensifier, and angle the Osteo Introducer Device tip approximately 20° to 40° cranially.
3. Using a mallet, advance the Osteo Introducer Device tip just past the posterior sacral cortex.
4. Rotate the image intensifier to get a lateral view of the sacrum, and adjust the superoinferior angulation of the Osteo Introducer Device so it can be advanced to the level of the superior portion of the S1 vertebral body.
5. Return to the angled AP view, and ensure that the mediolateral angulation of the Osteo Introducer Device is appropriate.
6. Return to the lateral view, and advance the Osteo Introducer Device to the level of the superior portion of the S1 vertebral body. Check imaging to avoid penetrating the anterior sacral cortex during Osteo Introducer Device placement.
7. If patient suffers from sacral insufficiency fractures on both lateral aspects of the sacrum, repeat the access steps on the contralateral side.

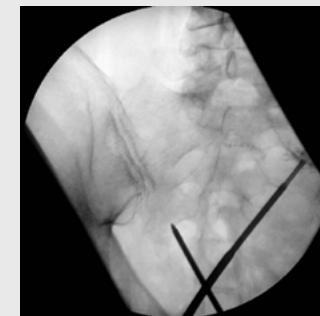
Note: the bilateral trajectories will likely result in contact of the access needles and may require staggering the cannulas or accessing one side at a time.



Lateral view
of the sacrum



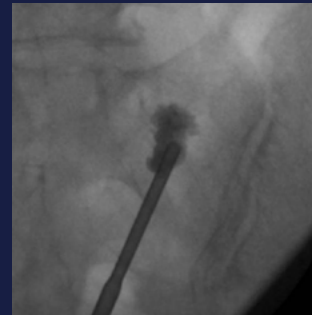Posterior view
of the sacrum



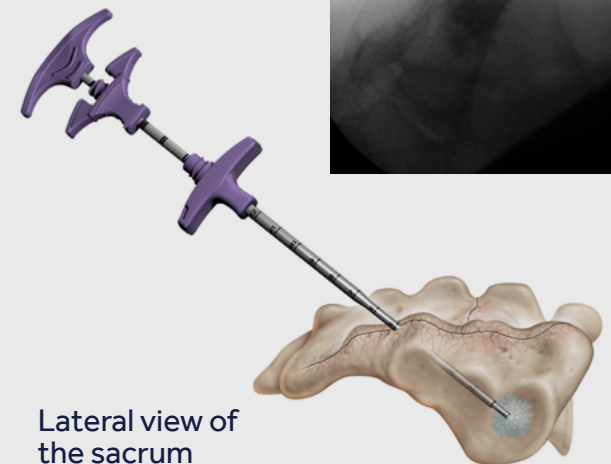
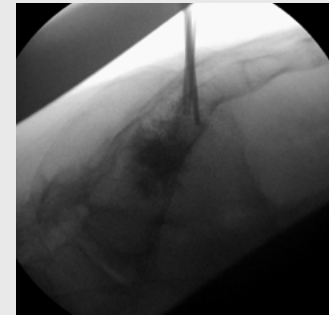
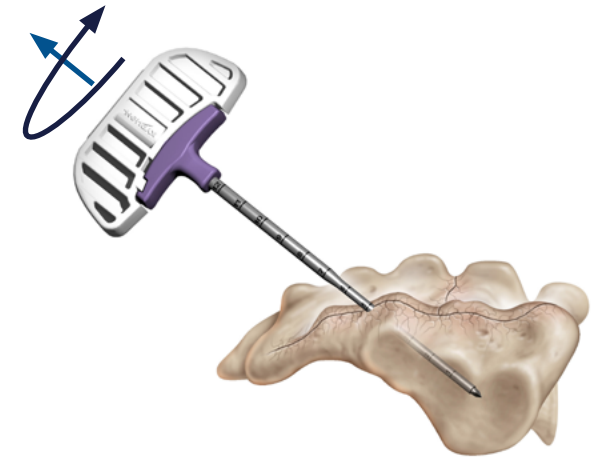ACCESSING THE SACRUM

Long-axis technique *(cement injection)*

1. When the cannula(s) is in place, carefully remove the stylet from the cannula by twisting the stylet handle counter clockwise and pulling away from the cannula. Be sure to hold the working cannula while performing the maneuver to maintain your placement.
2. Prepare the cement per the instructions for use.
3. When the cement has reached the doughy state, from the lateral view, place the bone filler device into the working cannula, and position the distal end to fill the center portion of the sacral ala.
4. Inject cement into the sacrum using both the lateral and the oblique AP views to monitor the process. There should be no anterior extravasation (anterior to the anterior border of the sacrum) as seen on the lateral view. There should be little to no extravasation into the neural foramina as seen on the oblique AP view.
5. While placing the cement in the sacrum, try to fill the center aspect of the sacral ala (between the SI joint and the neural foramina). Intermittently retract the needle from distal to proximal while placing the cement along the longitudinal axis of the sacrum targeting the fracture line. Cement volumes may range from 2 to 20 ml due to patient anatomy. An attempt should be made to fill the anterior two-thirds of the sacral ala while monitoring for medial and posterior cement migration.
6. Once the cement has been placed into the sacral ala, remove the bone filler device and use a tamp to ensure the cement has hardened. Re-insert the stylet into the cannula, and remove the working cannula(s) from the patient while following proper wound closure procedures.



Lateral view
of the sacrum



Lateral view of
the sacrum

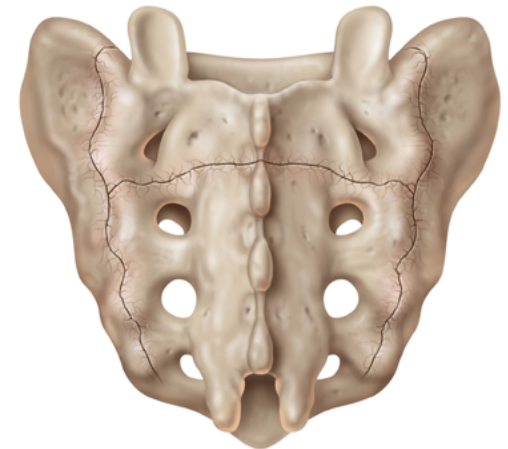


ACCESSING THE SACRUM

Short-axis technique

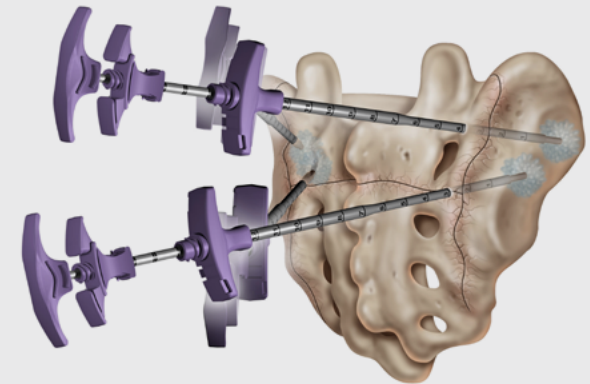
Imaging

- In the frontal plane, rotate the image intensifier cephalad to an AP plane.
- Ensure that a direct AP view is obtained by rotating the image intensifier to place the spinous processes in the center of the vertebral body.
- Rotate the image intensifier to the side opposite the treatment location to approximately 20° to 30° or to an angle along the longitudinal axis of the SI joint that aligns the inferior portion of the joint.
- Choose a starting point in the upper half of the sacrum halfway between the SI joint and a vertical line that joins the medial borders of the sacral neural foramina.



Posterior view
of the sacrum

Oblique view of
the sacrum

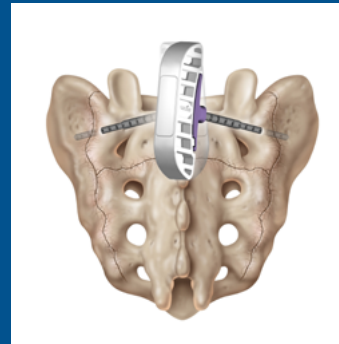


ACCESSING THE SACRUM

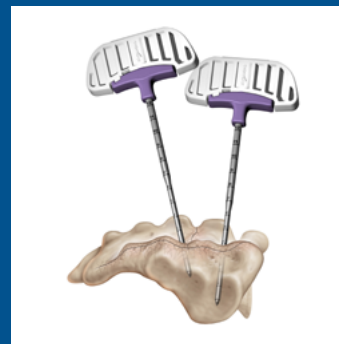Short-axis technique

1. Anesthetize the skin at the starting point, and make a stab incision with a scalpel blade.
2. Insert the Osteo Introducer Device parallel to the image intensifier.
3. Using a mallet, advance the Osteo Introducer Device tip just past the posterior sacral cortex and into the center one-third of the sacrum.
4. Rotate the image intensifier to get a lateral view of the sacrum, and advance the Osteo Introducer Device within the S1 vertebral body. Check imaging to avoid penetrating the anterior sacral cortex during Osteo Introducer Device placement.
5. If patient suffers from sacral insufficiency fractures on both lateral aspects of the sacrum, repeat the access steps on the contralateral side. The short axis technique may be applied both superior and inferior to the S1-S2 sacral foramen per the patient's anatomical and clinical conditions.

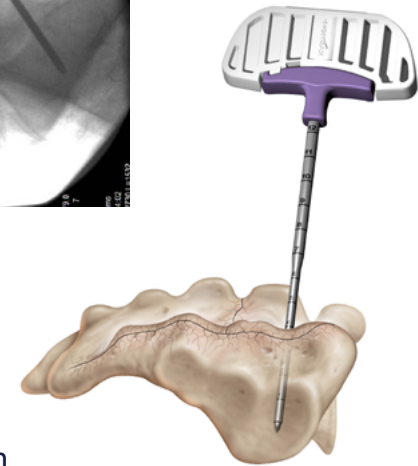
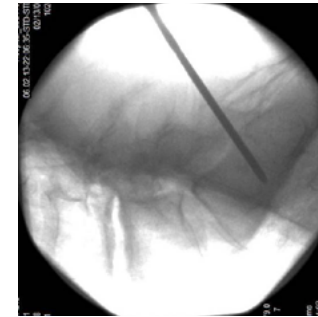
Note: the bilateral trajectories will likely result in contact of the access needles and may require staggering the cannulas or accessing one side at a time.



Posterior View of the sacrum with dual lateral access cannulas

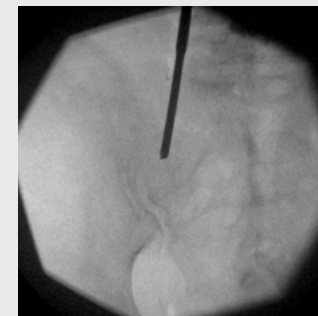
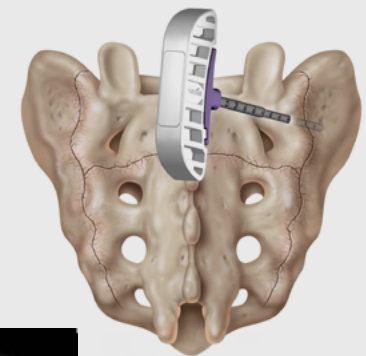


Lateral View of the sacrum with dual lateral access cannulas



Lateral view of the sacrum

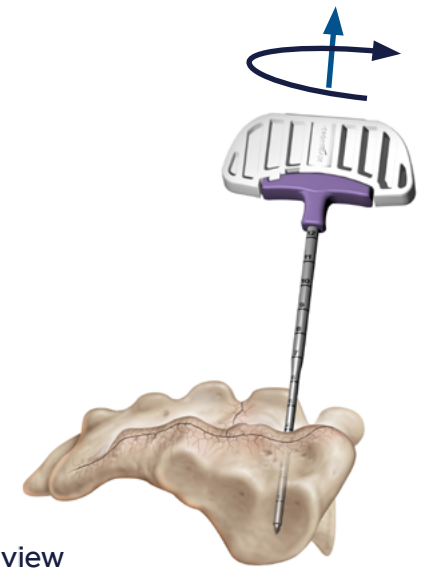
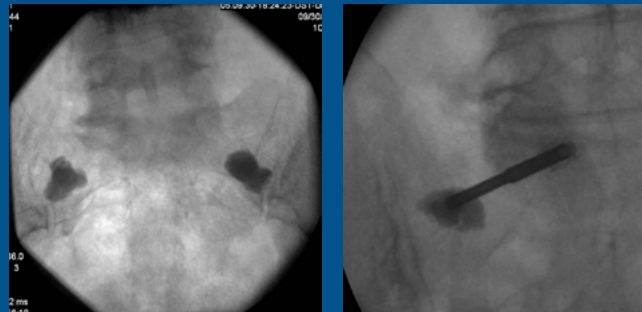
Posterior view of the sacrum



ACCESSING THE SACRUM

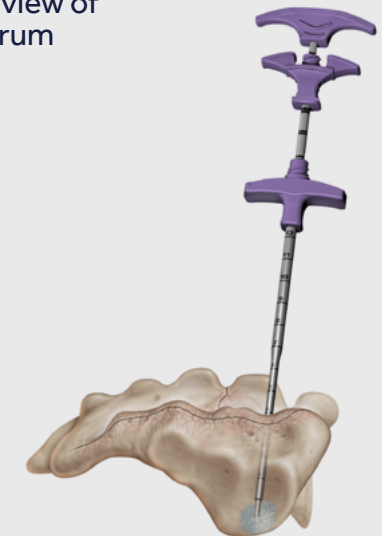Short-axis technique *(cement injection)*

1. When the cannula(s) is in place, carefully remove the trocar-tipped stylet from the cannula by twisting the stylet handle counterclockwise and pulling away from the cannula. Be sure to hold the working cannula while performing the maneuver to maintain your placement.
2. Prepare the cement per the instructions for use.
3. When the cement has reached the doughy state, place the bone filler device(s) into the working cannula(s).
4. Inject cement into the sacrum using both the lateral and the oblique AP views to monitor the process. There should be no anterior extravasation (anterior to the anterior border of the sacrum) as seen on the lateral view. There should be little to no extravasation into the neural foramina as seen on the oblique AP view.
5. While placing the cement in the sacrum, try to fill the center aspect of the sacral ala (between the SI joint and the neural foramina). Intermittently retract the needle from distal to proximal while placing the cement along the longitudinal axis of the sacrum targeting the fracture line. Cement volumes may range from 2 to 8 ml due to patient anatomy. An attempt should be made to fill the anterior two-thirds of the sacral ala while monitoring for medial and posterior cement migration.
6. Once the cement has been placed into the sacral ala, remove the bone filler device, and use a tamp to ensure the cement has hardened. Re-insert the stylet into the cannula, and remove the working cannula(s) from the patient while following proper wound closure procedures.



Lateral view
of the sacrum

Lateral view of
the sacrum



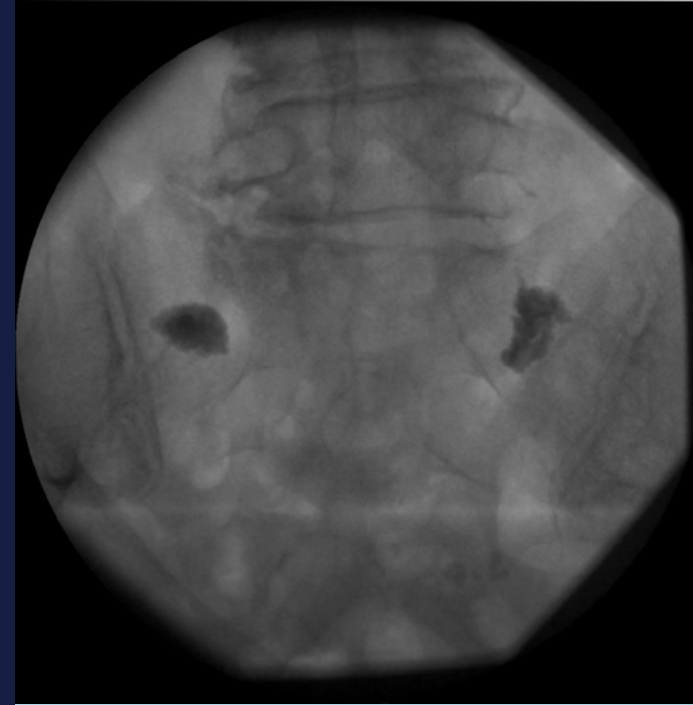
POST-OPERATIVE RECOMMENDATIONS

Post Op Imaging

- While the patient is still prone on the operative table, complete AP and lateral imaging after wound closure. If available, a CT can be used to obtain 3D imaging of the sacrum.

Post Procedure Positioning

1. The patient stays positioned on the operative table following cement injection for at least 5-10 minutes while the procedure is being completed. During this time, the bone cement can be tapped to verify it has hardened, the stylets are replaced and the osteo introducers are removed, and the skin incision wound is closed. This allows adequate time for the bone cement to harden during its setting phase and mitigate any risk of cement extravasation. This is also consistent with the existing timing guidance in the package insert regarding the handling characteristics.
2. A final set of fluoroscopic images should be taken following completion of the procedure before the patient is moved from the operative table.
3. The patient may ambulate with assistance in the hours immediately following transfer from the operating room to the recovery room, as the anesthesia wears off.
4. The patient should be monitored for several hours following the procedure for cardiovascular, respiratory, or neurologic dysfunction.



INDICATION AND RISK STATEMENT

The Kyphon V™ Osteo Introducer System is intended for percutaneous access to bone and for the delivery of bone cement, including during a kyphoplasty or vertebroplasty procedure.

The Kyphon V™ Bone Biopsy Device is intended for obtaining a bone biopsy specimen, including use during a kyphoplasty or vertebroplasty procedure.

The Kyphon Kurve™ Bone Filler Device is intended for the delivery of bone cement.

The Kyphon™ Cement Delivery System is intended for the delivery of bone cement, including use during a kyphoplasty or vertebroplasty procedure.

Kyphon HV-R™ Bone Cement and Kyphon Xpede™ Bone Cement are indicated for the treatment of pathological fractures of the vertebral body due to osteoporosis, cancer, or benign lesions using a cementoplasty (i.e. kyphoplasty or vertebroplasty) procedure. It is also indicated for the fixation of pathological fractures of the sacral vertebral body or ala using sacral vertebroplasty or sacroplasty. Cancer includes multiple myeloma and metastatic lesions, including those arising from breast or lung cancer, or lymphoma. Benign lesions include hemangioma and giant cell tumor. Pathologic fracture may include a symptomatic vertebral body microfracture (as documented by appropriate imaging and/or presence of a lytic lesion) without obvious loss of vertebral body height.

The Kyphon V™ Osteo Introducer System, Kyphon V™ Bone Biopsy Device, Kyphon Kurve™ Bone Filler Device and Kyphon™ Cement Delivery System are single use devices intended to contact body tissues. Do not reuse, reprocess, or resterilize. Reusing these devices carries the risk of contamination and may cause patient infection or cross-infection, regardless of the cleaning and resterilization methods. There is also an increased risk of the deterioration of the device performance due to the reprocessing steps, which may lead to patient injury or death.

For safe and effective use of Kyphon HV-R™ Bone Cement and Kyphon Xpede™ in Sacroplasty procedures, the physician should have specific training, experience and familiarity with the injection of bone cement into weakened or diminished bone in the sacrum.

Please see the Instructions for Use for the list of any contraindications for use.

Payer coverage for Sacroplasty may vary. Medtronic recommends providers review all payer coverage policies and/or call payers to determine coverage criteria and appropriate coding.

UC201710487 EN PMD019318-2.0

